



PATIENT PRESENTING CLINICAL SIGNS

PATIENT Sampson McKenzie History: Obese, multiple dermal nodules. Atopy – on Cytopoint. Fully excised oral melanoma (5/21) with no evidence of re-occurrence.

SPECIES Canine Physical Examination: N/A.

Urinalysis: SG 1.009, 3+ protein. Negative sediment. Culture pending.

BREED Beagle CBC: Band neutrophilia, monocytosis, mild thrombocytosis.

Serum Biochemistry: Mildly elevated globulins, ALP activity, and calcium. Elevated cholesterol.
Radiographic Findings: N/A.

SEX

MN

AGE

12 years

WEIGHT

49.5 #

INTERPRETED BY

Remo Lobetti, BVSc,
MMedVet (Med), PhD,
Dipl. ECVIM

ULTRASONOGRAPHIC EXAMINATION OF THE ABDOMEN

Urinary System

Full urinary bladder with a normal thickness and appearance of the wall. Normal anechoic urine with no sediment or uroliths evident.

Normal trigone area, proximal urethra, and iliac blood vessels.

Normal iliac lymph nodes. Ureters not visualized.

Normal renal size (left 6.4 cm, right 7 cm) with increased echogenic appearance, some loss of cortico-medullary differentiation, and normal pelvis and capsule. Bilateral cortical cysts.

Reproductive System

Small hypoechogenic prostate.

Adrenal Glands

Normal shape, echogenic appearance, size, and position. Left 1.83 x 0.58 cm, right 1.8 x 0.76 cm.

Spleen

Normal size and echogenic appearance. Smooth homogenous parenchyma, smooth curvi-linear capsule, and normal vasculature. Two mottled echogenic parenchymal masses – 1.2 x 1.4 cm (tail) and 1.5 x 2.2 cm (body) with resultant bulging of the overlying capsule.

Liver

Normal size and portal markings with a diffuse increased echogenic appearance. No nodules or masses evident. Full gall bladder containing normal anechoic bile. Normal appearance and thickness of the gall bladder wall. Normal bile duct.

Gastrointestinal

Normal appearance of the stomach, duodenum, small intestine, ileo-cecal junction, and colon with no loss of layering, normal wall thickness and peristaltic activity, and no distension of the lumen.

IMAGING PERFORMED BY

Dr Megan Cassels-Conway, DVM

HOSPITAL NAME

Central Broward Animal Hospital

REFERRING VET

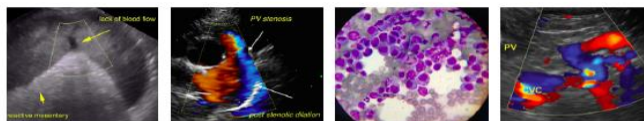
Dr Oms, DVM

INVOICE

302793

DATE

3/4/22



PATIENT *Pancreas*

Sampson McKenzie Normal size and echogenic appearance. Regular capsule. Normal echogenic appearance of the mesentery and fat surrounding the pancreas.

SPECIES *Free Abdomen*

Canine No mesenteric lymphadenomegaly.
No ascites.

BREED

Beagle **ULTRASONOGRAPHIC FINDINGS**

Primary Findings:

- SEX**
 - Splenic masses.
 - Hepatopathy.
- MN

AGE

Secondary Findings:

- 12 years
 - Age-related renal changes.

WEIGHT **INTERPRETATION OF THE FINDINGS & FURTHER RECOMMENDATIONS**

49.5 # Etiologies for the splenic masses would be hematomas, neoplasia, abscessation, and granulomas.

INTERPRETED BY

Remo Lobetti, BVSc,
MMedVet (Med), PhD,
Dipl. ECVIM

The most likely etiology for the hepatopathy would be fat infiltration with reactive, vacuolar, metabolic, and chronic hepatitis differential diagnoses. Infiltrative neoplasia would be a highly unlikely differential diagnosis.

Further assessment would be 3-view thoracic radiographs, FNA cytology of the splenic masses, possibly PTH assay, and if the urine culture is negative, then UPC.

IMAGING PERFORMED BY

Dr Megan Cassels-Conway, DVM

Specific therapy would be dependent on an etiological diagnosis.

HOSPITAL NAME

Central Broward Animal Hospital

REFERRING VET

Dr Oms, DVM

INVOICE

302793

DATE

3/4/22



PATIENT

Sampson McKenzie

SPECIES

Canine

BREED

Beagle

SEX

MN

AGE

12 years

WEIGHT

49.5 #

INTERPRETED BY

Remo Lobetti, BVSc,
MMedVet (Med), PhD,
Dipl. ECVIM

IMAGING PERFORMED BY

Dr Megan Cassels-
Conway, DVM

HOSPITAL NAME

Central Broward Animal
Hospital

REFERRING VET

Dr Oms, DVM

INVOICE

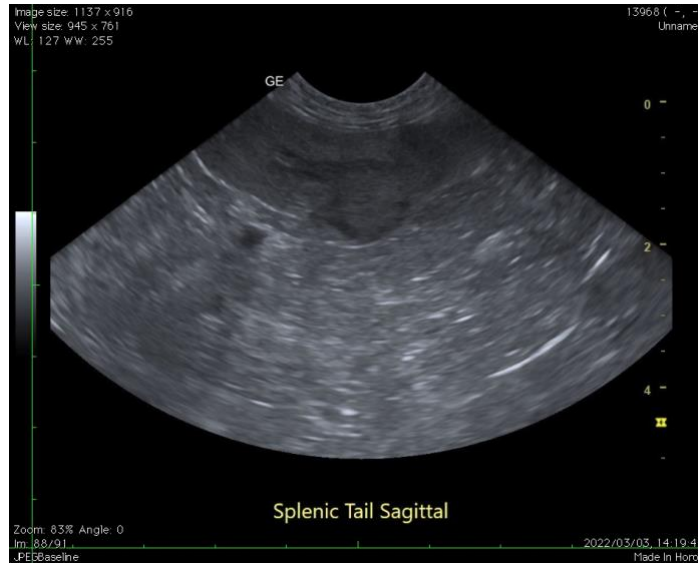302793

DATE

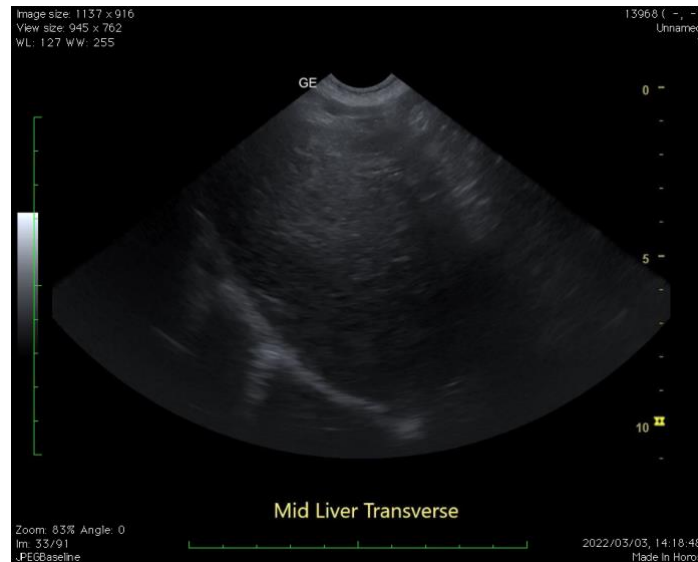3/4/22

IMAGES

Spleen



Liver



The information and recommendations provided are based on the images presented by the referring veterinarian. No evaluation can be communicated regarding pathology that was not visible in the image/video clips provided.

Thank you for this referral. If the clinical or image interpretation does not parallel your findings or if I can be of any further assistance, please contact me.

Remo Lobetti, BVSc, MMedVet (Med), PhD, Dipl. ECVIM (Internal Medicine)
rlobetti@mweb.co.za